


Contents lists available at [ScienceDirect](https://www.sciencedirect.com)

## European Journal of Surgical Oncology

journal homepage: [www.ejso.com](http://www.ejso.com)

## Prognostic factors value of germline and somatic brca in patients undergoing surgery for recurrent ovarian cancer with liver metastases



Valerio Gallotta <sup>a, \*</sup>, Carmine Conte <sup>a</sup>, Marco D'Indinosante <sup>b</sup>, Ettore Capoluongo <sup>c, d</sup>, Angelo Minucci <sup>d</sup>, Agostino Maria De Rose <sup>e</sup>, Francesco Ardito <sup>e</sup>, Felice Giuliani <sup>e</sup>, Andrea Di Giorgio <sup>f</sup>, Gian Franco Zannoni <sup>g</sup>, Anna Fagotti <sup>a, b</sup>, Christian Margreiter <sup>h</sup>, Giovanni Scambia <sup>a, b</sup>, Gabriella Ferrandina <sup>a, b</sup>

<sup>a</sup> Fondazione Policlinico Universitario A. Gemelli, IRCCS, UOC Ginecologia Oncologica, Dipartimento per la salute della Donna e del Bambino e della Salute Pubblica, Roma, Italy

<sup>b</sup> Università Cattolica del Sacro Cuore, Istituto di Ginecologia e Ostetricia, Roma, Italy

<sup>c</sup> Laboratory of Clinical Molecular and Personalized Diagnostics, Catholic University of the Sacred Heart, Roma, Italy

<sup>d</sup> Laboratory of Clinical Molecular and Personalized Diagnostics, Fondazione "Policlinico Universitario A. Gemelli" IRCCS, Rome, Italy

<sup>e</sup> Department of Surgical Sciences, Hepatobiliary Unit, Fondazione "Policlinico Universitario A. Gemelli", IRCCS, Catholic University of the Sacred Heart, Rome, Italy

<sup>f</sup> Division of General Surgery, Fondazione "Policlinico Universitario A. Gemelli", IRCCS, Rome, Italy

<sup>g</sup> Institute of Histopathology, Fondazione "Policlinico Universitario A. Gemelli", IRCCS, Catholic University of the Sacred Heart, Roma, Italy

<sup>h</sup> Department of Visceral, Transplant, and Thoracic Surgery, Medical University of Innsbruck, Innsbruck, Austria

### ARTICLE INFO

#### Article history:

Received 26 April 2019

Received in revised form

8 June 2019

Accepted 12 June 2019

Available online 13 June 2019

#### Keywords:

Hepatic metastasis

Recurrent ovarian cancer

Secondary cytoreduction

BRCA gene mutational status

Personalized medicine

### ABSTRACT

**Objective:** To describe accurately the oncological outcomes after hepatic resection (HR) in recurrent ovarian carcinoma (ROC) evaluating clinic-pathological variables and mutational status of BRCA1/2. Although HR is considered a challenging situation in ROC patients, assessment of BRCA1/2 mutational status seems to have a relevant clinical value to guide surgical therapy.

**Methods:** Patients who underwent HR for ROC at the Catholic University of Rome, between June 2012 and October 2017 were included. Exclusion criteria were represented by extra-abdominal disease and presence of diffuse peritoneal carcinomatosis requiring more than 2 bowel resections. Details relative to HR were collected and BRCA analysis was performed. Predictive factors of post-HR progression free survival (PHR-PFS) were assessed by univariate analyses using Cox-proportional hazard regression models.

**Results:** Thirty-four patients underwent HR within secondary cytoreductive surgery (SCS). Six patients (17.6%) presented with hepatic relapse only, while the remaining 28 patients (82.4%) had concomitant extra-hepatic disease.

In the whole series, the 3-yr PHR-PFS was 49.1% and the 3-yr post-HR overall survival was 72.9%. Univariate analysis of variables conditioning PHR-PFS showed that only BRCA mutational status played a statistically significant favourable role: the 3-yr PHR-PFS rate was 81.0% in BRCA mutated patient compared to 15.2% in wild type ones (p value: 0.001).

**Conclusions:** Our clinical analyses suggest that in ROC patients with liver disease the assessment of germline and somatic BRCA mutational status can help to select patients eligible for SCS.

© 2019 Elsevier Ltd, BASO ~ The Association for Cancer Surgery, and the European Society of Surgical Oncology. All rights reserved.

### Introduction

Despite the advances in cytoreductive efforts and the potential addition of bevacizumab to front line chemotherapy in advanced ovarian cancer, recurrence is a common event with >70% of women

\* Corresponding author. Fondazione Policlinico Universitario A. Gemelli, IRCCS, UOC Ginecologia Oncologica, Dipartimento per la salute della Donna e del Bambino e della Salute Pubblica, Roma, Italy.

E-mail address: [gallottav@gmail.com](mailto:gallottav@gmail.com) (V. Gallotta).

experiencing relapse within two years of diagnosis [1]. The standard treatment of recurrent ovarian cancer (ROC) patients has been traditionally represented by systemic chemotherapy chosen on the basis of the platinum sensitivity, defined as the interval between completion of first-line chemotherapy and relapse of disease [2]; however, this concept has been recently recognized as presenting a greater level of complexity given the influence of histotype, status of BRCA genes or homologous recombination deficiency (HRD), previous antiangiogenic treatment, pattern of relapse presentation, and other factors [2–5]. In this context, it has also to be acknowledged that the introduction of PARP inhibitors in second line, and, very recently, in first line treatment for BRCA mutated ovarian cancer patients, would open novel scenarios in terms of management of disease relapse [6,7].

Several retrospective studies [8,9], as well as a recently published Cochrane meta-analysis suggested that secondary cytoreductive surgery (SCS) could provide better clinical outcomes in platinum-sensitive ROC patients, in case of complete tumor cytoreduction, which has to be considered the goal to be achieved in order to provide a true clinical benefit [10,11]. However, the documentation of liver relapse at the time of SCS might be considered as a challenging surgical scenario, thus leading to preclude or limit the achievement of complete eradication of disease; indeed, several data have been published sustaining that hepatic resection (HR) can be carried out within SCS procedures in ROC patients with acceptable medical and surgical complications [12–21]. Moreover, since the concurrent resection of metachronous liver and extra-hepatic disease has been shown to provide long term survival in well selected cases bearing other solid tumors [22,23], it cannot be excluded that this approach may be of benefit also for ROC patients.

While waiting for prospective clinical studies on this specific issue, the identification of clinical and/or pathological parameters able to identify which patients could benefit the most from HR(s) would be useful in terms of personalization of treatment: apart from the absence of extra-abdominal disease, some variables have been consistently documented as predictors of better prognosis after HR(s), such as achievement of optimal cytoreduction, disease free interval (DFI) interval >12 months before HR(s), tumor-free margins, and single liver lesion [14–20].

Recent advances in the molecular characterization and natural history of this disease have opened novel perspectives based on the better prognosis and higher tumor sensitivity to platinum-based therapy in case of alterations of BRCA genes or HRD; moreover, a recently published study has suggested that assessment of mutational status of BRCA could be of help in the decision making approach to surgery versus chemotherapy in platinum sensitive ROC [24].

This retrospective study was aimed at analyzing the clinical outcome of ROC patients affected by liver disease who underwent HR(s) in the context of SCS; the prognostic role of clinico-pathological variables and mutational status of BRCA1/2 has been also investigated.

## Patients and methods

After obtaining the Institutional review board approval (CICOG-31-10-18\151), we performed a retrospective review and analysis of data on ROC patients undergoing HR(s) in the context of SCS at the Gynecologic Oncology Unit of the Catholic University of Rome, Italy. All patients had already provided a written informed consent for their data to be collected and analyzed for scientific purpose, according to our institutional policy.

Inclusion criteria were: clinical performance status 0–2 (Eastern Cooperative Oncologic Group-ECOG), platinum free interval  $\geq$ 6

months, high quality imaging (i.e. CT scan and/or PET/CT) documenting absence of extra-abdominal disease, and accurate characterization of site and pattern of disease.

Exclusion criteria were represented by preoperative and intraoperative assessment of extra-abdominal disease, and/or disease located in areas precluding the achievement of optimal cytoreduction, and presence of diffuse peritoneal disease requiring more than 2 bowel resections, presence of ascites.

Resectability of hepatic lesions was thoroughly discussed preoperatively and intraoperatively with hepatobiliary surgeons.

The following data were planned to be retrieved from medical records: age, body mass index (BMI), FIGO stage at the time of initial diagnosis, tumor histology and grade, duration of median platinum free interval (PFI), and pattern of relapse; details about patient features at the time of liver relapse were: age, BMI, number of previous lines of chemotherapy, duration of PFI before hepatic recurrence, number of liver lesions, and BRCA mutational status (germline or somatic).

Data relative to the operative outcomes of HR(s) were also collected: skin-to-skin operative time, estimated blood loss (EBL), length of hospital stay (LOS), Peritoneal Cancer Index (PCI), type of surgical procedures and residual tumor disease at the end of SCS. In addition, details relative to hepatic resection(s) were collected, including type of liver resections (e.g., wedge resection, segmentectomy, multisectionectomy, and lobectomy), and concomitant surgical procedures for any extrahepatic disease, if any. Hepatic resection(s) through segmentectomy or lobectomy were performed by hepatobiliary surgeons together with a gynecologic oncology fellow, while wedge resection(s) were carried out by experienced gynecologic oncology surgeons. Data about intra- and post-operative complications occurring within or after 30 days from surgery were retrieved, and surgical morbidity was classified according to Clavien-Dindo [25].

Genomic and somatic DNA were isolated from FFPE HGSOC sections in areas with a minimum neoplastic cellularity of 70% using an automated device (MagCore HF16 Plus, Diatech Lab Line, Jesi, Italy).

BRCA analysis was performed using the Devyser BRCA kit (Devyser, Hägersten, Sweden). Sequencing reactions were carried out with the MiSeq instrument (Illumina, CA, USA). NGS data were analyzed with the Amplicon Suite software (SmartSeq s.r.l., Novara, Italy) aligning reads to the HG19 reference genome, generating run metrics, by including sequencing depth, total read count, and quality, as previously reported [24]. The pipeline was performed following the literature recommendations [26].

## Statistical analysis

Descriptive analysis of data was carried out by Fisher's exact test for proportion for categorical data or Wilcoxon rank sum non parametric test for continuous variables. Post-HR progression free survival (PHR-PFS) was calculated from the date of SCS to documentation of disease progression or the date last seen. Post-HR overall survival (PHR-OS) would be calculated from the date of SCS to death of disease or the date last seen. Survival estimates would be analyzed by the Kaplan-Meier method, and the log rank test would be used to assess statistical significance. Univariate analysis of prognostic factors would be carried out by Cox's regression model with stepwise variable selection. The SPSS Statistical version 19 (SPSS Inc., Chicago, IL) was used for all analyses.

## Results

Between June 2012 and October 2017, 190 patients with ROC underwent SCS in our center; after evaluation of inclusion/

exclusion criteria, 34 patients undergoing HR(s) within SCS were selected for inclusion in this study.

Characteristics of patients at primary diagnosis are summarized in Table 1: most patients were stage III–IV (n = 29, 85.3%), serous histology (n = 32, 94.1%), and grade 3 (n = 30, 90.9%). All patients received platinum-based regimens in the adjuvant setting; median initial platinum free-interval was 21 months (range: 10–55).

As shown in Table 2, the median age at the time of hepatic resection(s) was 51.5 years (range: 31–72), and median BMI was 26 (range: 18–37). Six patients (17.6%) presented with hepatic relapse only, while the remaining 28 patients (82.4%) had concomitant extra-hepatic disease; peritoneal and spleen involvement were the most frequently involved sites followed by retroperitoneal disease.

Among cases bearing only liver disease, 4 had single lesion, and 2 had  $\geq 2$  nodules; of 28 patients bearing liver and other sites of disease, 15 presented single liver lesion, and 13 had  $\geq 2$  nodules. Details about BRCA 1/2 mutational status was available in 33 patients (germline = 23, somatic = 10). Of 20 BRCA mutated cases, 15 cases (75.0%) were shown to harbour BRCA1 mutation, 3 patients (15.0%) showed mutation of BRCA 2, and 2 cases (10.0%) showed mutation of both genes (Table S1).

There was no difference in the distribution of patient features at the time of hepatic relapse, according to the BRCA 1/2 mutational status (Table S2).

Table 3 summarizes the details of surgical procedures: HR(s) consisted of wedge or monosegmentectomy, bisegmentectomy, multisegmentectomy, and lobectomy, in 21, 7, 4, and 2 cases, respectively. The median PCI was 6 (range 2–12). Abdominal peritonectomy was necessary in 22 (64.7%) patients of which 14 (41.2%) underwent diaphragmatic resection. Splenectomy was carried out in 12 patients (35.3%); bowel resection was required in 3 (8.8%) patients. Hepato-celiac and aortic lymphadenectomy was performed in 7 (20.6%) and 4 (11.8%) patients, respectively. Only 4 patients (11.8%) underwent HR through minimally invasive approach.

Pathological evaluation of resected recurrent disease confirmed neoplastic involvement in all cases, and histology of recurrence was always consistent with the initial diagnosis. Resection margins of liver specimens were negative in all patients. Metastatic lymph

**Table 1**  
Patient characteristics at primary diagnosis.

Characteristics	N. (%)
<b>All patients</b>	34
FIGO stage at diagnosis	
I/II	5 (14.7)
III	26 (76.5)
IV	3 (8.8)
Histology	
Serous	32 (94.2)
Endometrioid	1 (2.9)
Clear cell	1 (2.9)
Grading	
G1/2	3 (8.8)
G3	30 (88.3)
n.a.	1 (2.9)
First line chemotherapy	
Carboplatin/paclitaxel	22 (64.7)
Carboplatin/paclitaxel/bevacizumab	9 (26.5)
Carboplatin/gemcitabine or carboplatin/PLD	2 (5.9)
Carboplatin alone	1 (2.9)
Platinum free interval	
$\geq 6$ –12 months	3 (8.8)
13–24 months	16 (47.1)
25–36	7 (20.6)
>36 n.a.	6 (17.6)
<b>PFI, months</b>	2 (5.9)
<b>Median (range)</b>	21 (10–55)

N.a. = not available.

**Table 2**  
Patient characteristics at the time of hepatic disease.

Characteristics	N. (%)
<b>All patients</b>	34
Age, yrs	
Median (range)	51.5 (31–72)
<b>BMI</b>	
Median (range)	26 (18–37)
No. chemotherapy lines before hepatic disease	
1	22 (64.7)
2	5 (14.7)
3	5 (14.7)
>3	2 (5.9)
Last chemotherapy before hepatic disease <sup>a</sup>	
Non platinum agents	2 (6.1)
Platinum based regimens	31 (93.9)
Platinum free interval before hepatic disease <sup>b</sup>	
<6 months	2 (6.4)
$\geq 6$ –12 months	5 (16.2)
13–24 months	11 (35.5)
25–36	11 (35.5)
n.a.	2 (6.4)
<b>PFI, months</b>	
Median (range)	23 (4–46)
Site of disease at relapse	
Liver only	6 (17.6)
Single lesion	4
$\geq 2$ lesions	2
Liver and other sites	28 (82.4)
Single lesion	15
$\geq 2$ lesions	13
CA-125 levels at the time of hepatic disease (I.U.)	
Median (range)	115 (15–6614)
BRCA 1/2 mutational status	
Wild-type	13 (38.3)
Mutated	20 (58.8)
N.a.	1 (2.9)

<sup>a</sup> Calculated on 33 patients since 1 patient was administered neo-adjuvant platinum containing chemotherapy at the time of secondary cytoreduction.

<sup>b</sup> Calculated on 31 patients treated with platinum containing chemotherapy at the time of secondary cytoreduction.

node involvement was observed in 4 out of 7 patients undergoing hepato-celiac lymphadenectomy.

Optimal cytoreduction (i.e. residual tumor  $\leq 1$  cm) was achieved in all patients; of these, absence of residual disease was obtained in 32 patients (94.1%).

Adjuvant chemotherapy after HR(s) was mainly represented by platinum based regimens (82.3%); olaparib was administered to 11 of 20 mutated patients (55.0%).

#### Peri-operative measures and morbidity

As far as peri-operative details are concerned, the median length of surgery was 373 min (range: 177–695), and the median length of hospital stay was 6 days (range: 3–30).

There were 2 (5.9%) intraoperative complications, including 1 lesion of the portal vein occurring during lymphadenectomy at hepatic hilum, and 1 diaphragmatic lesion due to lack of cleavage between liver and diaphragm as a consequence of previous surgery.

During the observation period, 10 patients (29.4%) had post-operative complications; only 5 of them (14.7%) were grade 3; in particular, 4 patients suffered from early complications including 2 patients experiencing abdominal abscess requiring drainage, 1 patient had ischemic heart disease managed with percutaneous transluminal coronary angioplasty, and 1 patient required ileostomy due to intestinal perforation. One patient experienced fever and pleural effusion requiring drainage >30 days after surgery. Overall, none of these complications was considered related to liver

**Table 3**  
Surgical procedures per patient.

N.	Hepatic resection	Peritonectomy	Splenectomy	Lymphadenectomy	Bowel resection	Number of procedures
1	X	—	—	—	—	1
2	X	—	—	—	—	1
3	X	—	—	—	—	1
4	X	—	—	—	—	1
5	X	—	—	—	—	1
6	X	—	—	—	—	1
7	X	X	—	—	—	2
8	X	X	—	—	—	2
9	X	X	—	—	—	2
10	X	X	—	—	—	2
11	X	X	—	—	—	2
12	X	X	—	—	—	2
13	X	X	—	—	—	2
14	X	X	—	—	—	2
15	X	X	—	—	—	2
16	X	—	X	—	—	2
17	X	—	—	Hepato-celiac	—	2
18	X	—	—	Hepato-celiac, aortic	—	2
19	X	—	—	Hepato-celiac	—	2
20	X	X	X	—	—	3
21	X	X	X	—	—	3
22	X	X	X	—	—	3
23	X	X	X	—	—	3
24	X	X	X	—	—	3
25	X	X	X	—	—	3
26	X	X	X	—	—	3
27	X	—	X	Aortic	—	3
28	X	X	—	Hepato-celiac	—	3
29	X	X	—	Hepato-celiac	—	3
30	X	—	—	Pelvic	X	3
31	X	X	X	—	X	4
32	X	X	X	Hepato-celiac	—	4
33	X	X	X	Hepato-celiac, aortic	—	4
34	X	X	—	Aortic	X	4

resection procedures.

*Survival analysis*

As of October 2018, median duration of follow-up since SCS was 24 months (range:7–75). Twelve patients (35.3%) experienced

**Table 4**  
Characteristics of patients experiencing recurrence after hepatic resection(s).

ID	Stage	BRCA mutation status	Previous relapse(s) N.	Sites of extrahepatic disease	N. of liver segment(s) (mm)	RT	PHR-DFS (months)	Site of subsequent recurrence	Treatment of subsequent recurrence	PHR-OS (months)	Status
1	IIIC	WT	0	Peritoneum	Multiple	0	10	Peritoneum	CT	21	DOD
2	IV	MUT	1	Peritoneum	Multiple	0	n.a.	n.a.	CT	32	DOD
3	IIIC	WT	0	Peritoneum	Single	0	14	Peritoneum	CT	18	AWD
4	IV	MUT	0	Peritoneum	Multiple	0	5	Peritoneum	CT	22	AWD
5	IIB	MUT	0	Peritoneum	Single	0	40	Peritoneum	Surgery	63	NED
6	IIB	WT	0	Peritoneum	Single	0	27	Peritoneum	CT	75	AWD
7	IIIC	n.a.	0	Peritoneum	Single	2	11	Peritoneum	CT	16	AWD
8	IIIC	WT	3	Peritoneum	Single	0	30	Peritoneum	CT	39	DOD
9	IIIC	WT	0	None	Single	0	13	Lung	RT	40	AWD
10	IIIA	WT	0	Peritoneum	Single	0	10	Peritoneum	CT	24	AWD
11	IV	WT	0	Peritoneum	Single	0	20	Peritoneum	CT	44	NED
12	IIIC	WT	4	Peritoneum	Multiple	0	3	Peritoneum	CT	7	DOD
				Hepato-Celiac LNs				Lung	Mediastinic LNs		

WT= BRCA wild-type; MUT = BRCA mutated; LNs = lymph nodes; CT = chemotherapy; RT = radiotherapy; PHR-PFS = post-HR progression-free survival; PHR-OS = post-HR overall survival; NED = no evidence of disease; AWD = alive with disease; DOD = dead of disease; n.a. = not available.

**Table 5**  
Univariate analysis of prognostic parameters of post-relapse progression free survival.

Variable	N. (%)	HR (95% CI)	p value
FIGO stage at diagnosis			
I/II	5 (14.7)	1.075 (0.228, 5.073)	0.927
III/IV	29 (85.3)		
BRCA 1/2 mutational status			
Wild-type	13 (38.3)	0.064 (0.008, 0.516)	<b>0.001</b>
Mutated	20 (58.8)		
N.a.	1 (2.9)		
PARP Inhibitors therapy			
No	20 (58.8)	1.887 (0.397–8.977)	0.418
Yes	11 (32.4)		
n.a.	3 (8.8)		
Platinum free interval at the time of hepatic disease <sup>a</sup>			
≤12 months	7 (22.6)	1.472 (0.310, 6.984)	0.624
>12months	22 (71.0)		
n.a.	2 (6.4)		
No. of relapse(s) before hepatic disease			
One	22 (64.7)	0.606 (0.163, 2.258)	0.450
Multiple	12 (35.3)		
No. of hepatic segment(s) with disease			
One	19 (55.9)	1.508 (0.466, 4.888)	0.489
Multiple	15 (44.1)		
Site of disease at hepatic resection			
Liver only	6 (17.7)	2.951 (0.378, 23.037)	0.278
Liver and other sites	28 (82.3)		

<sup>a</sup> Calculated on 31 patients treated with platinum containing chemotherapy at the time of secondary cytoreduction; PARP= Poly (ADP-ribose) polymerase.

relapse of disease after hepatic resections (Table 4): the most prevalent site of relapse was represented by peritoneal carcinomatosis, while liver disease was documented in only 2 cases. In the whole series, median PHR-PFS was 35 months; the 3-yr PHR-PFS was 49.1%.

As shown in Table 5, univariate analysis of variables conditioning PHR-PFS showed that only BRCA mutational status played a statistically significant favourable role: 3 (15.0%) of 20 patients with BRCA mutation developed relapse of disease, compared to 8 (61.5%) of 13 patients with wild type BRCA gene. The 3-yr PHR-PFS rate was 81.0% in BRCA mutated patient compared to 15.2% in wild type ones (p value: 0.001) (Fig. 1).

Death of disease was documented in 4 (11.8%) patients (wild type BRCA = 3, mutated BRCA = 1) in the whole series, the 3-yr PHR-OS was 72.9%.

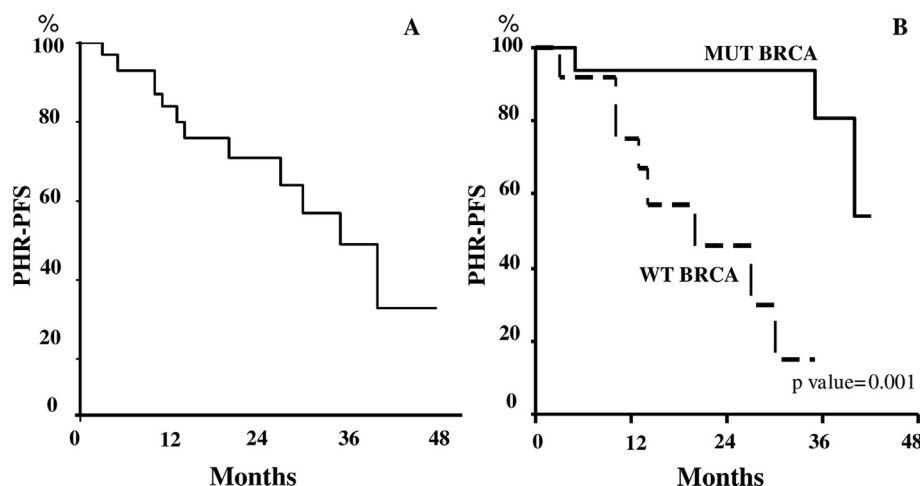
## Discussion

To our knowledge, this represents one of the largest series focused on the role of HR(s) within SCS in platinum sensitive ROC patients (Table S3). We report in the whole series a median PHR-PFS of 35 months and a 3-yr PHR-PFS of 49.1%, a figure which well matches with the previous literature. Interestingly enough, among the 12 patients experienced disease relapse after HR(s), only 2 progressed within the liver. Moreover, we first report that the documentation of BRCA gene mutation(s) is associated with better PFS after HR(s), thus providing a molecularly based line of evidence helping to choose the therapeutic approach to this, sometimes disputed, clinical setting.

Indeed, up to now, indications for HR(s) within SCS in ROC patients has been generally based on variables shown to be associated with a higher chance of complete tumor eradication, such as disease confined to liver only, presence of single lesion, and small size of liver disease [12–20]. However, HR(s) at SCS has been shown to provide clinical benefit also in ROC patients bearing extra-hepatic disease [12–20], as testified also in other gynecological malignancies and colorectal cancer [21,27,28]. In this context, additional parameters influencing the natural history of ovarian cancer, might have a relevant prognostic role, such as platinum sensitivity, and molecular features: indeed, multiple studies have documented that BRCA mutation provides a subgroup of OC patients with better outcome compared to wild-type counterpart [29–31].

In our series, BRCA 1/2 gene mutations were documented in 58.8% of cases, a figure which would have been expected considering that 12 out of 34 patients (35.3%) received ≥2 lines of chemotherapy, and 27 patients were still platinum sensitive before HR(s). Someone could argue that the impressive difference in terms of PHR-PFS between BRCA mutated versus BRCA wild type patients (3-yr PHR-PFS: 81.0% versus 15.2%, respectively, p value: 0.001) might be related to the association of BRCA mutation with classical features of better prognosis [32]. However, we failed to demonstrate any association of BRCA mutation with PFI length or other features at the time of liver relapse.

The presence of BRCA 1/2 mutation was the only variable associated with the clinical outcome after HR(s); in this context, we have to acknowledge that 32 out of 34 patients (94.1%) were left with no visible disease, and negative margins of HR(s). Therefore, in our series, two of the most frequently reported unfavourable prognostic factors have been overcome, thus leading to a more



**Fig. 1.** Post-hepatic resection PFS (PHR-PFS) in the whole series (A) and according to BRCA 1/2 mutational status (B).

homogeneous group, in which only BRCA 1/2 mutational status has emerged as a favourable parameter.

Despite the relatively small sample size which could have limited the power of the statistical analysis, the retrospective nature of the study, and the administration of olaparib only in 11 out of 20 BRCA mutated patients, we think that our findings could be of interest, and might open perspectives in terms of management of liver relapse in OC patients; documentation of BRCA mutation might add additional information to the current profile of ROC patients, and might be used in the future to reinforce the attitude to afford hepatic resection(s).

Until then, our study confirms the concept that the presence of liver metastases should not preclude to attempt secondary cytoreductive surgery on the basis of potential morbidity: indeed, literature data did not report death of disease, and major complications only exceptionally have resulted to be related to hepatic resection procedures [12–20]. Obviously, the need to discuss the management of liver metastasis on an individual basis in a multidisciplinary context has to be highlighted: careful evaluation of preoperative imaging together with an expert hepatobiliary surgeon is mandatory. Furthermore, all cases require a dedicated anesthesiology team with extensive experience in complicated liver and oncological surgery including liver transplantation and extensive hepatectomy [33–35]. Moreover, in experienced hands at high volume, tertiary centers, minimally invasive surgery could be considered an effective surgical approach in selected patients with resectable liver disease [33–37]. In our opinion, early detection of liver metastasis, characterization of molecular features of cancer disease and appropriate choice of multimodal treatment are very important for improving the outcomes of patients with ROC.

In conclusion, this study provides an accurate and detailed understanding of the oncological outcomes after surgery for hepatic ROC patients. Furthermore, unique clinicopathological and genetic features were identified that can help predict the prognosis. These findings are highly suggestive of biologic heterogeneity in ROC with liver disease and future studies might reveal genetic signatures associated with PHR-PFS, possibly opening the way for prognosis stratification, targets of treatment, and a more personalized surgical management.

Therefore, we are planning to promote a multi-institutional collection of data relative to hepatic resection(s) in ROC patients in a large scale, in order to validate this issue more robustly.

### Conflict of interest statement

The authors declare that they have no conflict of interest.

### Appendix A. Supplementary data

Supplementary data to this article can be found online at <https://doi.org/10.1016/j.ejso.2019.06.023>.

### References

- [1] Siegel RL, Miller KD, Jemal A. Cancer statistics, 2019. *CA Cancer J Clin* 2019;69(1):7–34.
- [2] Wilson MK, Pujade-Lauraine E, Aoki D, Mirza MR, Lorusso D, Oza AM, et al. Participants of the fifth ovarian cancer consensus conference. Fifth ovarian cancer consensus conference of the gynecologic cancer InterGroup: recurrent disease. *Ann Oncol* 2017;28(4):727–32.
- [3] Peres LC, Cushing-Haugen KL, Anglesio M, Wicklund K, Bentley R, Berchuck A, et al. Histotype classification of ovarian carcinoma: a comparison of approaches. *Gynecol Oncol* 2018;151(1):53–60.
- [4] Kurnit KC, Coleman RL, Westin SN. Using PARP inhibitors in the treatment of patients with ovarian cancer. *Curr Treat Options Oncol* 2018 Nov 15;19(12):1. <https://doi.org/10.1007/s11864-018-0572-7>.
- [5] Ferrandina G, Legge F, Salutati V, Paglia A, Testa A, Scambia G. Impact of pattern of recurrence on clinical outcome of ovarian cancer patients: clinical considerations. *Eur J Cancer* 2006;42(14):2296–302.
- [6] Pujade-Lauraine E, Ledermann JA, Selle F, Gebski V, Penson RT, Oza AM, et al. SOLO2/ENGOT-Ov21 investigators. Olaparib tablets as maintenance therapy in patients with platinum-sensitive, relapsed ovarian cancer and a BRCA1/2 mutation (SOLO2/ENGOT-Ov21): a double-blind, randomised, placebo-controlled, phase 3 trial. *Lancet Oncol* 2017;18(9):1274–84.
- [7] Moore K, Colombo N, Scambia G, Kim BG, Oaknin A, Friedlander M, et al. Maintenance olaparib in patients with newly diagnosed advanced ovarian cancer. *N Engl J Med* 2018;379(26):2495–505.
- [8] Suh DH, Kim HS, Chang SJ, Bristow RE. Surgical management of recurrent ovarian cancer. *Gynecol Oncol* 2016;142(2):357–67.
- [9] Al Rawahi T, Lopes AD, Bristow RE, Bryant A, Elattar A, Chattopadhyay S, et al. Surgical cytoreduction for recurrent epithelial ovarian cancer. *Cochrane Database Syst Rev* 2013;2. CD008765.
- [10] Tian WJ, Chi DS, Sehoul J, Tropé CG, Jiang R, Ayhan A, et al. A risk model for secondary cytoreductive surgery in recurrent ovarian cancer: an evidence-based proposal for patient selection. *Ann Surg Oncol* 2012;19(2):597–604.
- [11] du Bois A, Vergote I, Ferron G, et al. 2. Randomized controlled phase III study evaluating the impact of secondary cytoreductive surgery in recurrent ovarian cancer: AGO DESKTOP III/ENGOT ov20. Abs.5501. Chicago: ASCO Meeting; June 2017.
- [12] Chi DS, Fong Y, Venkatraman ES, Barakat RR. Hepatic resection for metastatic gynecologic carcinomas. *Gynecol Oncol* 1997;66(1):45–51.
- [13] Yoon SS, Jarnagin WR, Fong Y, DeMatteo RP, Barakat RR, Blumgart LH, et al. Resection of recurrent ovarian or fallopian tube carcinoma involving the liver. *Gynecol Oncol* 2003;91(2):383–8.
- [14] Bosquet JG, Merideth MA, Podratz KC, Nagorney DM. Hepatic resection for metachronous metastases from ovarian carcinoma. *HPB (Oxford)* 2006;8(2):93–6.
- [15] Merideth MA, Cliby WA, Keeney GL, Lesnick TG, Nagorney DM, Podratz KC. Hepatic resection for metachronous metastases from ovarian carcinoma. *Gynecol Oncol* 2003;89(1). 16–21c.
- [16] Abood G, Bowen M, Potkul R, Aranha G, Shoup M. Hepatic resection for recurrent metastatic ovarian cancer. *Am J Surg* 2008;195(3):370–3.
- [17] Pekmezci S, Saribeyoglu K, Aytac E, Arvas M, Demirkiran F, Ozguroglu M. Surgery for isolated liver metastasis of ovarian cancer. *Asian J Surg* 2010;33(2):83–8.
- [18] Roh HJ, Kim DY, Joo WD, Yoo HJ, Kim JH, Kim YM, et al. Hepatic resection as part of secondary cytoreductive surgery for recurrent ovarian cancer involving the liver. *Arch Gynecol Obstet* 2011;284(5):1223–9.
- [19] Niu GC, Shen CM, Cui W, Li Q. Hepatic resection is safe for metachronous hepatic metastases from ovarian cancer. *Cancer Biol Med* 2012;9(3):182–7.
- [20] Kolev V, Pereira EB, Schwartz M, Sarpel U, Roayaie S, Labow D, et al. The role of liver resection at the time of secondary cytoreduction in patients with recurrent ovarian cancer. *Int J Gynecol Cancer* 2014;24(1):70–4.
- [21] Bacalbasa N, Dima S, Brasoveanu V, David L, Balescu I, Purnichescu-Purtan R, et al. Liver resection for ovarian cancer liver metastases as part of cytoreductive surgery is safe and may bring survival benefit. *World J Surg Oncol* 2015;13:235.
- [22] Carpizo DR, D'Angelica M. Liver resection for metastatic colorectal cancer in the presence of extrahepatic disease. *Lancet Oncol* 2009;10(8):801–9.
- [23] Adam R, Chiche L, Aloia T, Elias D, Salmon R, Rivoire M, et al. Association Française de Chirurgie. Hepatic resection for noncolorectal nonendocrine liver metastases: analysis of 1,452 patients and development of a prognostic model. *Ann Surg* 2006;244(4):524–35.
- [24] Marchetti C, De Leo R, Musella A, D'Indinosante M, Capoluongo E, Minucci A, et al. BRCA mutation status to personalize management of recurrent ovarian cancer: a multicenter study. *Ann Surg Oncol* 2018;25(12):3701–8.
- [25] Dindo D, Demartines N, Clavien PA. Classification of surgical complications: a new proposal with evaluation in a cohort of 6336 patients and results of a survey. *Ann Surg* 2004;240(2):205–13.
- [26] Capoluongo E, Ellison G, López-Guerrero JA, Penault-Llorca F, Ligtenberg MJL, Banerjee S, et al. Guidance statement on BRCA1/2 tumor testing in ovarian cancer patients. *Semin Oncol* 2017 Jun;44(3):187–97.
- [27] Kamel SI, de Jong MC, Schulick RD, Diaz-Montes TP, Wolfgang CL, Hirose K, et al. The role of liver-directed surgery in patients with hepatic metastasis from a gynecologic primary carcinoma. *World J Surg* 2011;35(6):1345–54.
- [28] Rahusen FD, Cuesta MA, Borgstein PJ, Bleichrodt RP, Barkhof F, Doesburg T, et al. Selection of patients for resection of colorectal metastases to the liver using diagnostic laparoscopy and laparoscopic ultrasonography. *Ann Surg* 1999;230(1):31–7.
- [29] Yang D, Khan S, Sun Y, Hess K, Shmulevich I, Sood AK, et al. Association of BRCA1 and BRCA2 mutations with survival, chemotherapy sensitivity, and gene mutator phenotype in patients with ovarian cancer. *J Am Med Assoc* 2011 Oct 12;306(14):1557–65.
- [30] Harter P, Johnson T, Berton-Rigaud D, Park SY, Friedlander M, Del Campo JM, et al. BRCA1/2 mutations associated with progression-free survival in ovarian cancer patients in the AGO-OVAR 16 study. *Gynecol Oncol* 2016;140(3):443–9.
- [31] Lesnock JL, Darcy KM, Tian C, Deloia JA, Thrall MM, Zahn C, et al. BRCA1 expression and improved survival in ovarian cancer patients treated with intraperitoneal cisplatin and paclitaxel: a Gynecologic Oncology Group Study.

- Br J Cancer 2013 Apr 2;108(6):1231–7.
- [32] Hollis RL, Churchman M, Gourley C. Distinct implications of different BRCA mutations: efficacy of cytotoxic chemotherapy, PARP inhibition and clinical outcome in ovarian cancer. *OncoTargets Ther* 2017;10:2539–51.
- [33] Gasparri ML, Grandi G, Bolla D, Gloor B, Imboden S, Panici PB, et al. Hepatic resection during cytoreductive surgery for primary or recurrent epithelial ovarian cancer. *J Cancer Res Clin Oncol* 2016 Jul;142(7):1509–20.
- [34] Gallotta V, Conte C, Giudice MT, Nero C, Vizzielli G, Gueli Alletti S, et al. Secondary laparoscopic cytoreduction in recurrent ovarian cancer: a large, single-institution experience. *J Minim Invasive Gynecol* 2018;25(4):644–50.
- [35] Gallotta V, Ferrandina G, Vizzielli G, Conte C, Lucidi A, Costantini B, et al. Hepatoceliac lymph node involvement in advanced ovarian cancer patients: prognostic role and clinical considerations. *Ann Surg Oncol* 2017 Oct;24(11):3413–21.
- [36] Nguyen KT, Laurent A, Dagher I, Geller DA, Steel J, Thomas MT, et al. Minimally invasive liver resection for metastatic colorectal cancer: a multi-institutional, international report of safety, feasibility, and early outcomes. *Ann Surg* 2009 Nov;250(5):842–8.
- [37] Gallotta V, Fagotti A, Fanfani F, Ferrandina G, Nero C, Costantini B, et al. Laparoscopic surgical management of localized recurrent ovarian cancer: a single-institution experience. *Surg Endosc* 2014 Jun;28(6):1808–15.